

## THE TELECARDIOGRAM

W. EINTHOVEN

*Translated by*

HENRY W. BLACKBURN JR., M.D.

MINNEAPOLIS, MINN.

TWO lectures by W. Einthoven in May and November, 1905, were the source of an article on "The Telecardiogram" in the *Archives Internationales de Physiologie* 4:132, 1906. This fascinating work is the first organized presentation of normal and abnormal electrocardiograms recorded with the string galvanometer. These were made with galvanometer and recording apparatus in Einthoven's laboratory, the impulses transmitted through telephone wire from the patients in a hospital some distance away. Einthoven's explanations for the recorded phenomena are for the most part remarkably clear and accurate, if not complete. The following is a somewhat free translation of the bulk of the paper. An earlier translation of the first portion of this paper, on the technical aspects of "long distance" recording, appeared in the *AMERICAN HEART JOURNAL* 49:77, 1955.

Modern terminology is used primarily to promote readability, but certain vernacular terms are left for their historical interest. Einthoven refers to waves as summits, had no term for complex, and had not yet numbered his lead derivations. For example, he writes of "current taken from right hand to left foot" rather than potential difference in Lead II.

Translation begins with paragraph 35.

35\* Fig. 16 is a reproduction of the first long-distance electrocardiogram we recorded, that of a healthy and vigorous man, the current derived from the

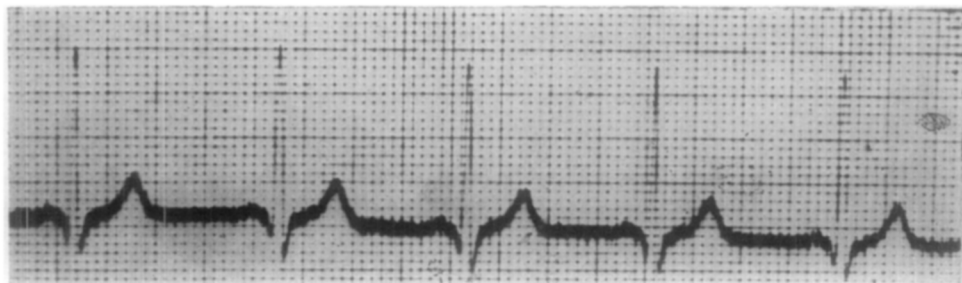


Fig. 16.—D. J. Derived from right hand to left hand.

From the Laboratory of Physiological Hygiene, University of Minnesota, Minneapolis, Minn.  
Received for publication April 6, 1955.

\*The numbers of both paragraphs and figures are those of the original paper.

two hands.\* It differs in no way from the record made with the subject in the laboratory beside the galvanometer. In each instance the five summits, P produced by auricular systole, Q,R,S, and T by ventricular systole, are identical in form and amplitude. In this subject the R wave is particularly high, corresponding to a potential difference of two millivolts.†

36. We will now examine cardiograms from patients hospitalized with divers cardiac diseases. In examining patients we are obviously motivated by the desire to cure their disease. Such, indeed, is the ultimate goal of the physician. Unfortunately, we must be quite modest since cure is not so readily obtainable. We must initially seek to understand cardiac function in detail and the causes of its numerous disturbances. With clearer outlook based on this knowledge we may be able in the remote future to relieve suffering and restore health to patients.

37. Fig. 17 presents the left hand-left foot electrocardiogram of a patient with mitral valve disease, predominantly insufficiency.

One notes specially the upwardly directed complex of colossal amplitude. It reaches almost 30 mm., which corresponds to a potential difference of 3 millivolts.

38. I have no comparable electrocardiogram obtained from the left hand-left foot. We would be in error, nevertheless, to consider this form as characteristic of mitral disease. Our diagnosis of valvular defect should not rest exclusively on the electrocardiogram since it does not record actual valve motion. The tracing is rather a manifestation of cardiac muscle contraction and is modified only to the degree that defective valve action influences this contraction.

39. The way in which the heart contracts depends largely upon the extent of disease in the muscle itself and the degree of compensation extant. In this particular case we must compare the degree of insufficiency with the magnitude of the other mitral defects. Only extensive study will reveal the full significance of the electrocardiogram.

40. In comparison, Figs. 18 and 19 are telecardiograms on patients with aortic insufficiency. The recording is from left hand-left foot and the waves are the reverse of those in the case of mitral insufficiency, the principal ventricular deflection being downward.

41. Mitral insufficiency provokes a predominant right ventricular hypertrophy, and aortic insufficiency a left ventricular hypertrophy. It is natural to presume that right hypertrophy is accompanied by development of an upright R and left hypertrophy by a downward R in electrocardiograms obtained from left hand-left foot.

42. This supposition is confirmed in Fig. 20 from a patient with arteriosclerosis and marked left heart hypertrophy. The R wave is directed downward with an amplitude corresponding to 2 millivolts potential difference.

---

\*This telecardiogram was recorded March 22, 1905. As a result of careful preparation the first attempt was an immediate success. To date, February 24, 1906, we have recorded a hundred cardiograms and several murmurs from hospitalized patients with no interruption of our operation. The galvanometer and recording apparatus and the communicating wires to the hospital have remained in perfect condition.

†The considerable R amplitude in this case was partly occasioned by the patient's physical exertion just before the experiment. He had gone by bicycle from our laboratory to the hospital.

Fig. 17.

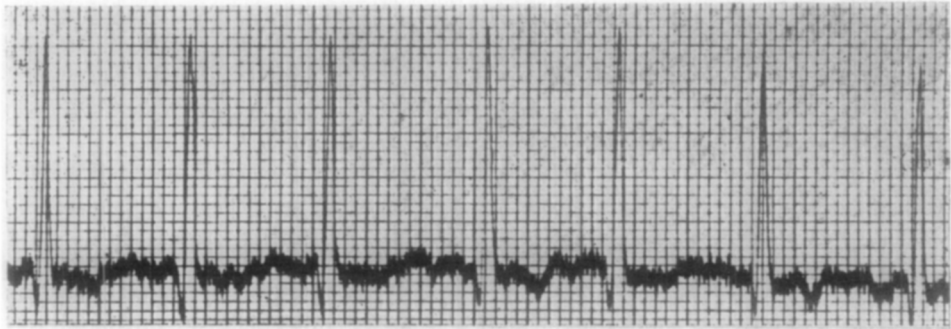


Fig. 18.

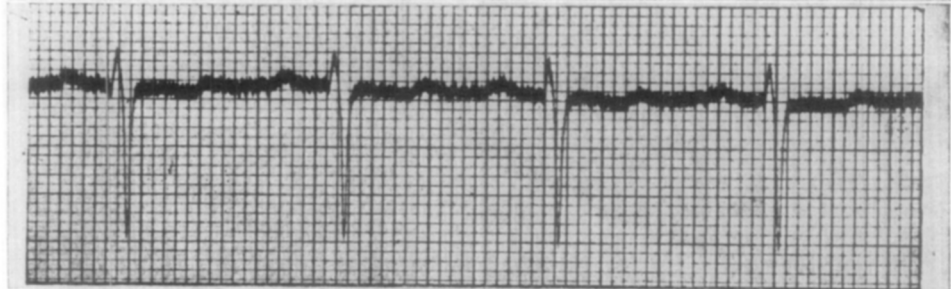

Fig. 19.

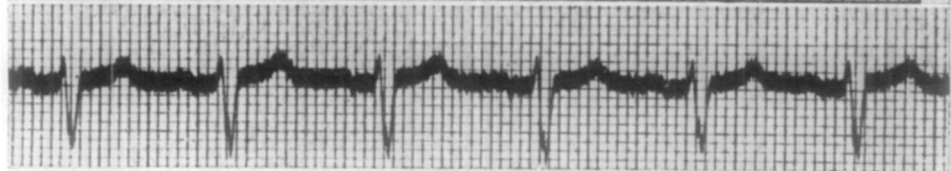

Fig. 20.

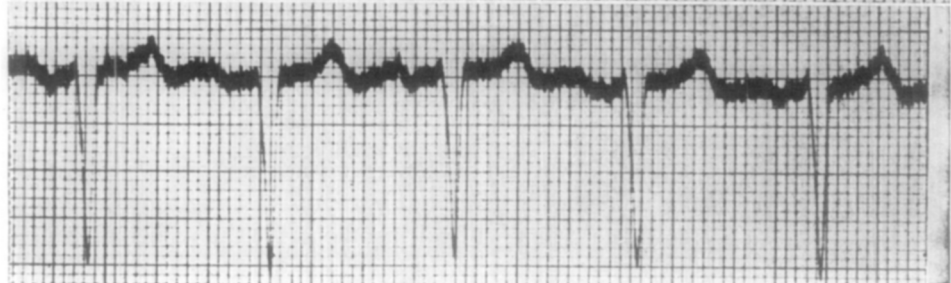


Fig. 17.—A. B. Mitral insufficiency—left hand to left foot.

Fig. 18.—B. H. S. Aortic insufficiency—left hand to left foot.

Fig. 19.—C. d. G. Aortic insufficiency—left hand to left foot.

Fig. 20.—J. V. J. Left ventricular hypertrophy—left hand to left foot.

43. Fig. 21 reproduces the telecardiogram of a patient with mitral stenosis without insufficiency and is taken from left hand-left foot. Note especially the characteristic form of the P wave, clearly accentuated and separated into three or four components.

44. This augmentation and prolongation of auricular systole is evidently related directly to the existence of mitral stenosis. The stenotic obstruction to blood flow causes a compensatory effect on the part of auricular contraction. To

my knowledge no one has previously been able to demonstrate this change in the left auricle, which is the most important of the two. The method of venous pulse recording, so valuable in study of the right auricle, has no application to study of the pulmonary veins in man, due to insurmountable anatomic obstacles.

45. In a second case of mitral stenosis, recorded from right hand-left foot in Fig. 22, the P wave is less prolonged but enormously elevated in comparison to the normal P in Figs. 7 and 8.

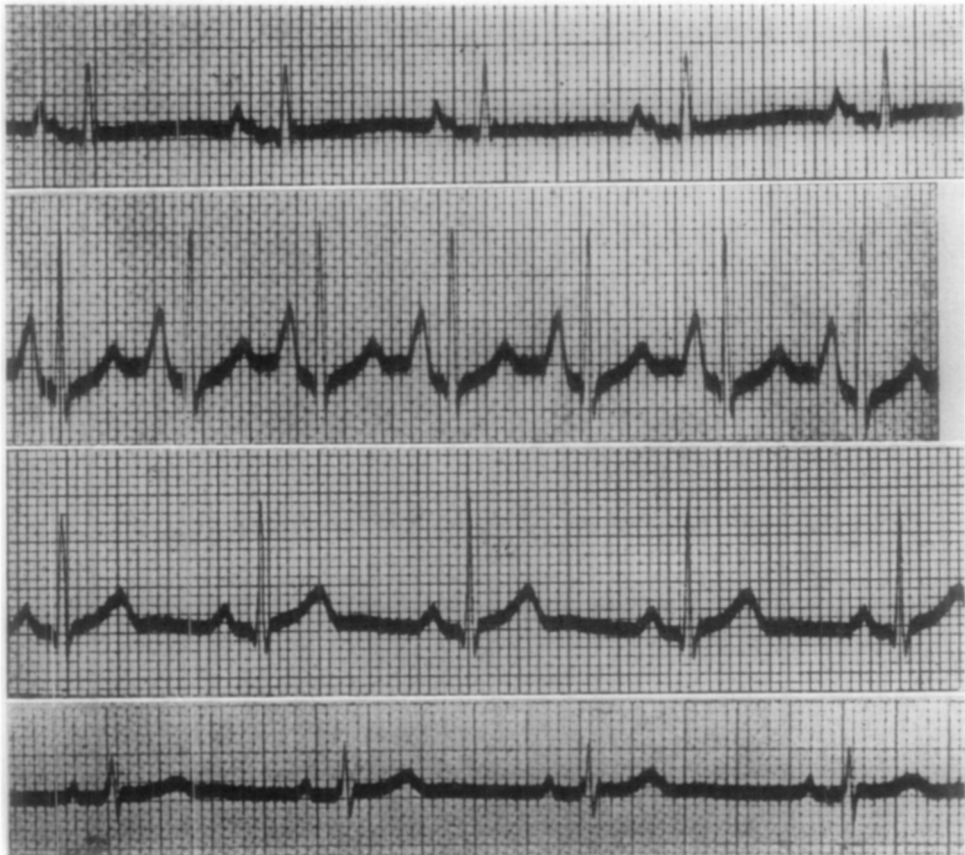


Fig. 21.

Fig. 22.

Fig. 7.

Fig. 8.

Fig. 21.—V. d. A. Mitral stenosis—left hand to left foot.

Fig. 22.—G. d. R. Mitral stenosis—right hand to left foot.

Fig. 7.—M. Right hand to left foot.

Fig. 8.—M. Left hand to left foot.

46. I have reproduced in Fig. 23 a most remarkable electrocardiogram from a patient with degenerative heart disease. The current is derived from right hand-left foot. We observe here that following the T wave, the last deflection in all our other electrocardiograms, there appears another wave. This peak, which we call U, terminates about 0.5 sec. after the onset of systole. This demonstrates in this pathologic case that systole lasts at least 0.5 sec. and is characterized by both an irregular and prolonged contraction.



47. Fig. 24, a left hand-left foot tracing from a case of congenital heart disease, is difficult to analyze in all its detail. In the upward directed complex we observe a notching not seen in a normal electrocardiogram.

48. We see remarkable changes in the waves in instances of functional disturbance from intemperate sport activity. And again, a great number of other abnormal situations, too numerous to mention here, exercise their influence on the electrocardiogram.

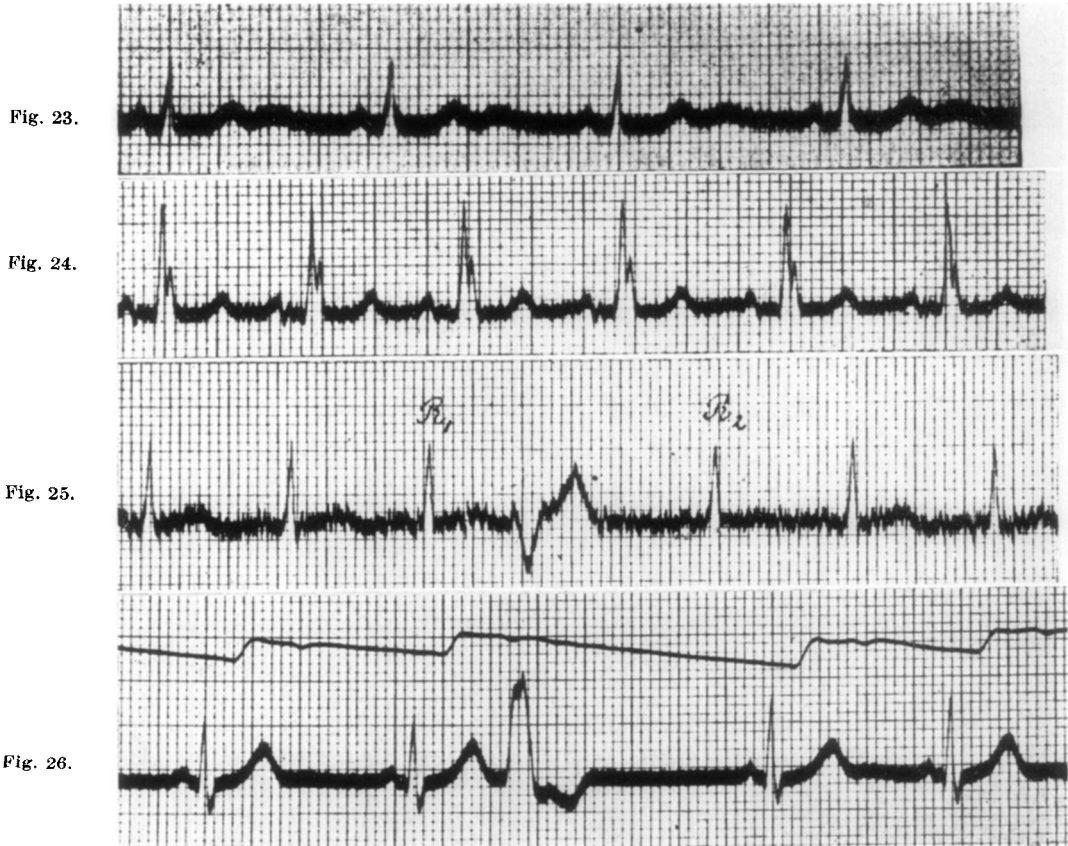


Fig. 23.—A. V. Y. Degenerative heart disease—right hand to left foot.

Fig. 24.—Ch. N. Congenital heart disease—left hand to left foot.

Fig. 25.—D. H. Convalescence in typhoid fever—right hand to left hand.

Fig. 26.—R. Dropped beat—right hand to left hand.

49. Anomalies in heart position can modify the form of the electrocardiogram in the presence of normal cardiac function. Since it is precisely the manner in which the heart functions that we are trying to deduce with an electrocardiogram, we must pass judgment independent of the effect of heart position on the tracing. This is why we must examine recordings on each subject derived from different vantages. Practically, we have always applied the three derivations right hand-left hand, right hand-left foot, and left hand-left foot.

50. I would now like to draw attention to a phenomenon observed in the course of our work which has occasioned considerable surprise.

51. It is a well-known fact that in a person with a regular pulse the rhythm may suddenly be interrupted. From time to time a beat is dropped in a regular series of beats. This irregularity is especially found in persons who have suffered debilitating illness, such as typhoid fever. One would expect to see at the moment of the dropped pulse beat an electrocardiographic complex greatly diminished in amplitude or completely absent. It is therefore quite remarkable that at the moment of the dropped pulse beat there develops a relatively strong potential, often more intense than that of the normal ventricular complex.

52. Fig. 25 is a reproduction of the electrocardiogram in a patient convalescing from typhoid fever. The tracing is a bit tremulous but can otherwise be regarded as normal. Actually this tremor does not originate in potentials from cardiac contraction but from those of skeletal muscle, as I will demonstrate at another occasion. Between beats  $R_1$  and  $R_2$  an atypical complex appears. This atypical beat is the sole abnormality in a series of normal beats.

53. Fig. 26 is the simultaneous record of pulse and electrocardiogram made in our laboratory on a patient who had typhoid fever two years previously. We find that the pulse wave is absent shortly after the electrocardiographic manifestation of an atypical beat.

54. It is of note that the latter occurs a little before we would expect the normal beat in the electrocardiogram. There is reason, therefore, to consider the process accompanying the atypical complex as the cause of the dropped pulse. This abnormality of cardiac function consists of an extrasystole followed by a compensatory pause.

55. With this convalescent patient we made a striking observation. While we in the laboratory observed the galvanometer deflections the clinician in the hospital, Prof. Nolen, took the subject's pulse. Each time we observed an atypical deflection we warned the clinician of it by a short telephonic signal. He found after each warning signal a dropped beat in the pulse.

56. With careful palpation one can only detect a dropped beat toward the end of the instant a normal beat is awaited. Since the atypical galvanometer deflection appears before the expected beat it allows us to predict the absent pulse. Thus were we able, to the great surprise of Prof. Nolen, to warn him telephonically an instant before he was to observe a dropped beat.

58. It should be explained that this pulse wave was obtained from a tambour over the carotid. Though it seems unlikely, it is not impossible that altered blood flow in the jugular vein could have influenced the arterial curve.

59. Our observations at this time are insufficient to satisfactorily explain this negative pulse wave, but the phenomenon is so obvious I have thought it well not to pass over it. The depression at  $n$  in Fig. 27 is not an artifact since it is seen only at this point in a long series of beats and it occurs in another series at almost the same interval after an extrasystole. In Fig. 29 it is seen at  $n$ , 0.28 sec. after the atypical beat, and in Fig. 27, 0.32 sec. following. These intervals appear rather great to me and seem to establish that an atypical contraction exerts a relatively prolonged influence.

60. As seen in Fig. 28, it sometimes happens that an atypical beat occurs late. One then observes the interesting fact that the pulse is hardly disturbed.

61. It has long been known that cardiac contractions occur without producing a peripheral pulse. They have been described as extrasystoles, or inopportune beats, and their origin distinguished in auricles, bundle of His, or ventricles. They have been spoken of also as frustrated beats since the contraction is inadequate to overcome aortic pressure.

62. However, in these explanations we have failed to recognize the essence of the phenomenon. For example in Fig. 28 we cannot speak of an extrasystole, or of a frustrated beat, since the beat occurs in time and the pulse produced is quite evident.

63. The cause of the phenomenon must be sought in the manner in which the heart contracts. In describing extrasystoles we have probably been deceived by the findings on auscultation and by the strength of the pulse. We have thought that extra beats would inevitably be weaker the closer they followed the normal beat.

64. We find that, in reality, atypical beats occurring immediately after a normal beat differ little from those occurring after a normal, or nearly normal, pause. This is clearly seen in comparing Figs. 26 and 27 with Fig. 28. The time interval between normal and abnormal beats in Fig. 28 is on the order of six times greater than in Figs. 26 and 27 (end of T to beginning of QRS) while the amplitudes are not much larger.

65. Our viewpoint is confirmed by Fig. 29 in a right hand-left foot record from the same subject. The first extrasystole comes after a rather long pause and produces a prominent pulse wave *p*, while the second succeeds the normal beat almost immediately, producing only a small negative pulse wave at *n*.

66. There is an insignificant difference in the electrical appearance of the two abnormal beats.

67. I hardly need to say our conclusion is that the heart is already able to contract strongly soon after the end of the refractory period. This phenomenon is entirely in contradiction to some prevalent ideas about cardiac function.

68. It is more than probable that our atypical beats explain the phenomena called bigeminy of the heart, hemisystole, and alternans, of which the vague explanations given to date should be for the most part rejected.\*

69. Fig. 30 is the electrocardiogram of a patient with bigeminy clinically, a typical "permanent slow pulse." We found 80 heart beats and a peripheral pulse of 40 per minute. This is a right hand-left foot tracing, at normal speed, with sensitivity one-half normal to keep the image within the plate border.

---

\*No one should think, from these opinions, that I wish to discount the merit of many clinicians studying these same problems by mechanical recording techniques. Since I speak now of the telecardiogram this is not the place to discuss the extensive bibliography on the subject of cardiac innervation and function. I would like, however, to make exception and mention particularly two outstanding studies: *The Study of the Pulse* by James MacKenzie and *Die Arrhythmie als Ausdruck . . .* by Professor Wenckebach.

I would like to express my personal opinion that one has been unable to establish with certainty the nature of extrasystoles with mechanical methods of investigation. In this sense electrical techniques have in a real way allowed us to make a step forward.

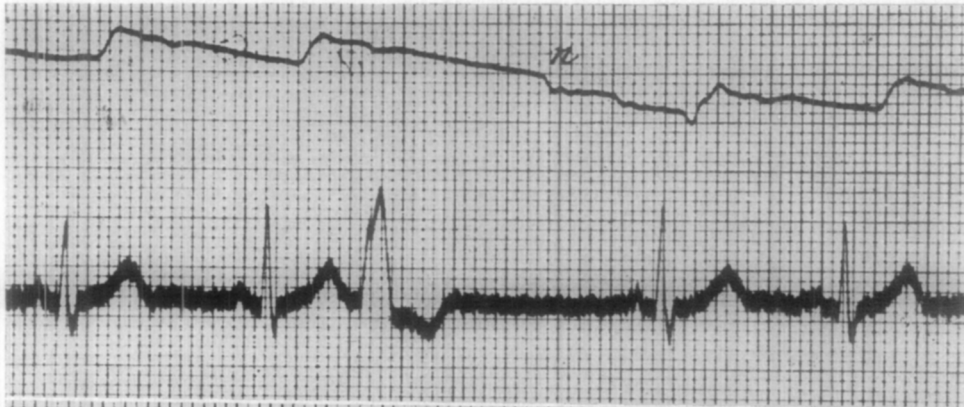


Fig. 27.

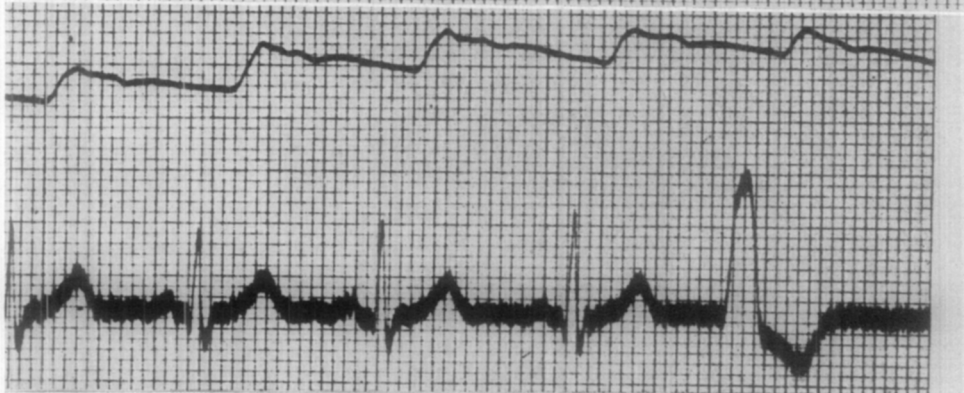

Fig. 28.

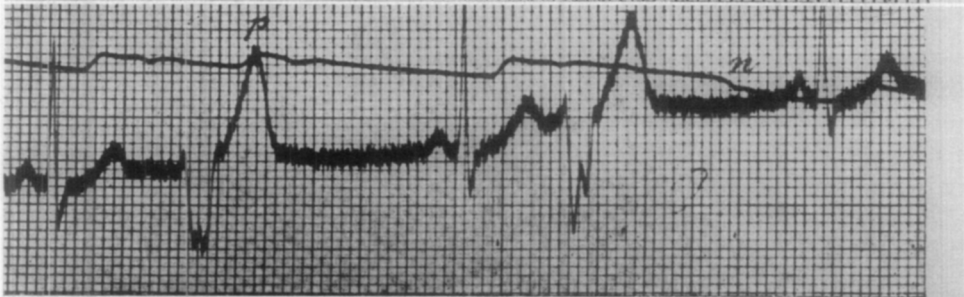


Fig. 29.

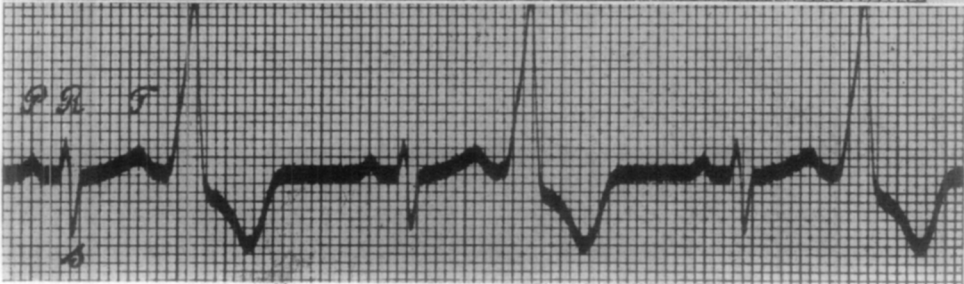


Fig. 30.

- Fig. 27.—R. Dropped beat—right hand to left hand.  
Fig. 28.—R. Extrasystole without dropped beat—right hand to left hand.  
Fig. 29.—R. Atypical beats—right hand to left foot.  
Fig. 30.—S. K. Bigeminy—right hand to left foot. 1 mm. along abscissa = 0.04 sec. 1 mm. along ordinate =  $2 \times 10^{-4}$  volts.

70. The normal complexes on this tracing are unremarkable. The P wave is quite distinct, the Q is absent, and the S prominent. After each normal beat there is an immediately occurring extrasystole with upward direction and great amplitude corresponding to 4 millivolts potential difference.\*

71. On occasion we observed a series of normal beats, interrupted at intervals by an extrasystole. Another time we found three successive extrasystoles, absolutely identical. While again, we were able to discern two different types of atypical beat.

72. I am afraid of going into excessive detail with further consideration of these phenomena. Before going on I would like to make two further comments concerning atypical contractions.

73. First, they are much more prevalent than one would suppose. Usually one would not suspect extrasystoles in a patient unless dropped beats were found in the pulse. However, in grossly irregular hearts it is difficult to determine the type of irregularity by palpation and virtually impossible to detect extrasystoles.

74. Thus it may happen that in a patient with an unequal and irregular pulse of 150 one would not think extrasystoles were present, and the galvanometer would indicate the contrary, Fig. 31 giving an example.

75. To conclude this review of telecardiograms I will give consideration to the relationship between auricular and ventricular systole. We know that in most instances this relationship is quite intimate, all ventricular beats being preceded by auricular, and all auricular beats followed by ventricular. It is rather important to measure the interval between auricular and ventricular action.

76. To determine this interval with mechanical recording we must have simultaneous arterial and venous pulses, which often gives difficulty. The electrocardiogram, to the contrary, permits easy and precise measurement. I refer to Fig. 9, a fast speed record, in which 1 mm. along the abscissa represents 0.01 sec. We find an interval of 0.175 sec. from the beginning of auricular to the beginning of ventricular systole, and 0.055 sec. between the end of auricular and beginning of ventricular systole. In Fig. 10, a similar type recording on another subject, the intervals are smaller, 0.13 and 0.035 sec., respectively.

77. According to Mackenzie there is a lag in the relationship between the two parts of the heart when the As-Vs (P-R) interval exceeds 0.2 sec. In this situation certain drugs, such as widely used digitalis, are dangerous. With the electrocardiogram it would be simple to follow step by step the influence of various drugs on this interval. My comments on As-Vs interval measurement are generally applicable to all quantitative investigation of heart function. The system in which our curves are traced greatly facilitates such measurements.

78. With a rapid pulse, auricular systole follows ventricular so closely that the normal rest period disappears. It can even happen that ventricular and auricular systole occur partly at the same time. The action curves of the two parts of the heart are partially superimposed, and there is thus overlapping of

---

\*In the thesis of Dr. Goteling Vinnis, Leyde, 1905, we find the mechanical cardiogram of the same subject. We see in these curves a reduplicated pulse. The second part of the curve is repeated regularly, sometimes with the same amplitude, sometimes smaller than the first part.

beats. When auricular systole is so early that the ventricle is still refractory to stimulation, the regular succession of action of the two parts of the heart is disturbed.

79. These considerations are confirmed in Figs. 31 and 32, the latter from a patient with dextrocardia produced by left-sided pleural exudate. The pulse

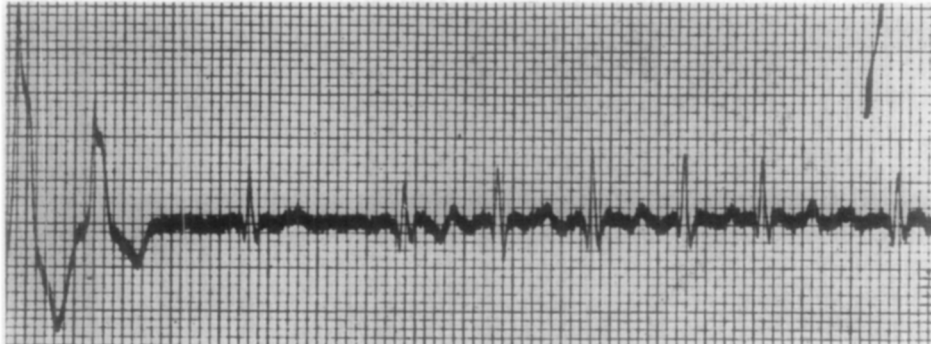


Fig. 31

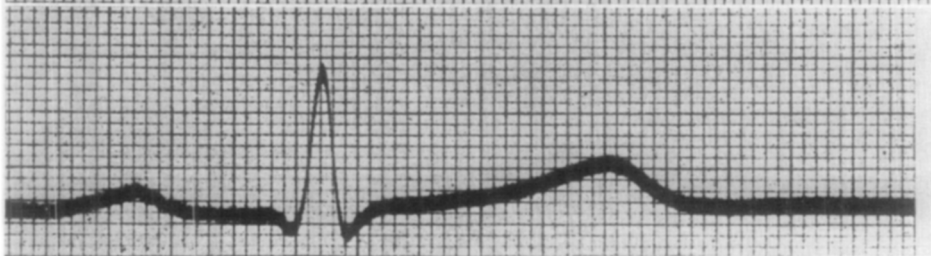


Fig. 9.

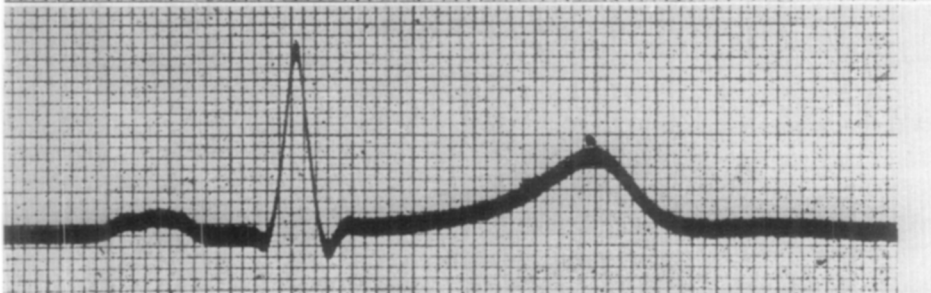


Fig. 10.

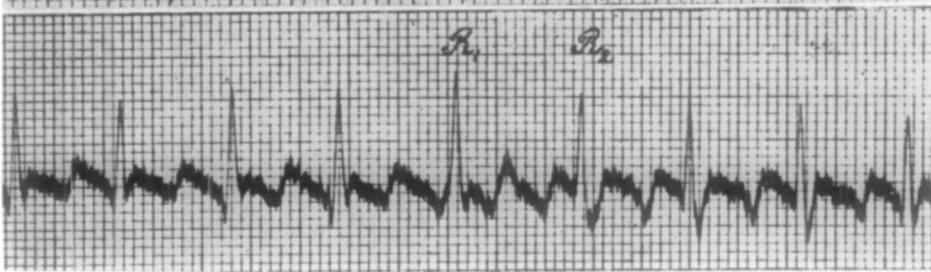

Fig. 32.

- Fig. 31. H. V. W. Irregular, unequal pulse. Left hand to left foot.
- Fig. 9.---M. Normal. Right hand to left foot. 1 mm. along abscissa = 0.01 sec.
- Fig. 10.---Th. Normal. Right hand to left foot. 1 mm. along abscissa = 0.01 sec.
- Fig. 32. -L. Dextrocardia from pleural effusion. Left hand to left foot.

is rather regular and rapid at 126. The cardiac rest period is completely absent. While elsewhere in the figure one finds two small waves between R waves, note three similar peaks between  $R_1$  and  $R_2$ . The middle wave probably represents a nonconducted auricular beat.

80. In Fig. 31 note an analogous instance, and that in both figures the ventricular complexes present all sorts of little irregularities nonexistent in normal hearts.

81. If there is an obstacle to transmission of excitation from one part of the heart to the other, regular succession of action is disturbed, and something besides an auricular beat is needed to produce a ventricular systole (heart block).

82. It may also occur that all rapport between auricular and ventricular function ceases. The two parts of the heart then work independently, each with its own rhythm. This can be induced in mammalian hearts by section of the communicating bundle between auricle and ventricle, the bundle discovered by and named after W. His, Jr. One must take care not to so mutilate the heart that it stops. This experiment, first described by His, has been successfully repeated by other investigators, including Fredericq and Humblet in Liege and Hering in Prague. After section or crushing of the bundle the animal heart displays the remarkable picture of completely independent auricular and ventricular action, termed *allorhythmia*.

83. With the electrocardiogram one can readily visualize the condition of block and allorhythmia. Fig. 33 is the electrocardiogram of a dog under deep chloroform narcosis. The current was conducted from the right anterior extremity to the left posterior, and the tracing is, in general form, analogous to the human electrocardiogram. Auricular waves are marked  $a_1$ ,  $a_2$ , etc. Note that the T wave, upward in most human electrocardiograms, is here directed downward.

84. Between  $E_1$  and  $E_2$  the peripheral end of the vagus nerve was stimulated. Cardiac systole goes on to completion, and an auricular beat  $a_2$  occurs, after which the heart remains quiet until the stimulus is ended.

85. At the end of the excitation an initial auricular beat  $a_3$  appears, not followed by a ventricular beat. At this moment a block exists. Only at  $a_4$  is the block relieved and normal conduction reestablished.

86. With deeper anesthesia and stronger vagal stimulation heart block is accentuated. Fig. 34 is a similarly made record on another dog. After a long vagal induced pause several auricular beats in succession appear before the first ventricular beat develops.

87. The auricular oscillations begin after an arrest of 3 seconds, and only the fifth beat is followed by ventricular systole.

88. Figs. 33 and 34 show that P waves are modified by vagal stimulation while there is no difference in the ventricular complexes (Fig. 33) before and after excitation.

89. Fig. 1 of Plate I is the tracing of a third dog in which there is no association between auricular and ventricular systole, an absolute allorhythmia. The auricular peaks indicated by  $a_1$ ,  $a_2$ , etc. occur at regular intervals and some are even associated with ventricular beats. However, though the auricular rate is around 55, the ventricular is about 35 per minute.

90. I plan to treat in more detail on another occasion phenomena produced by vagal stimulation, and the circumstances in which one can cause block and allorhythmia in the dog heart. Now let us return to the human electrocardiogram.

Fig. 33.

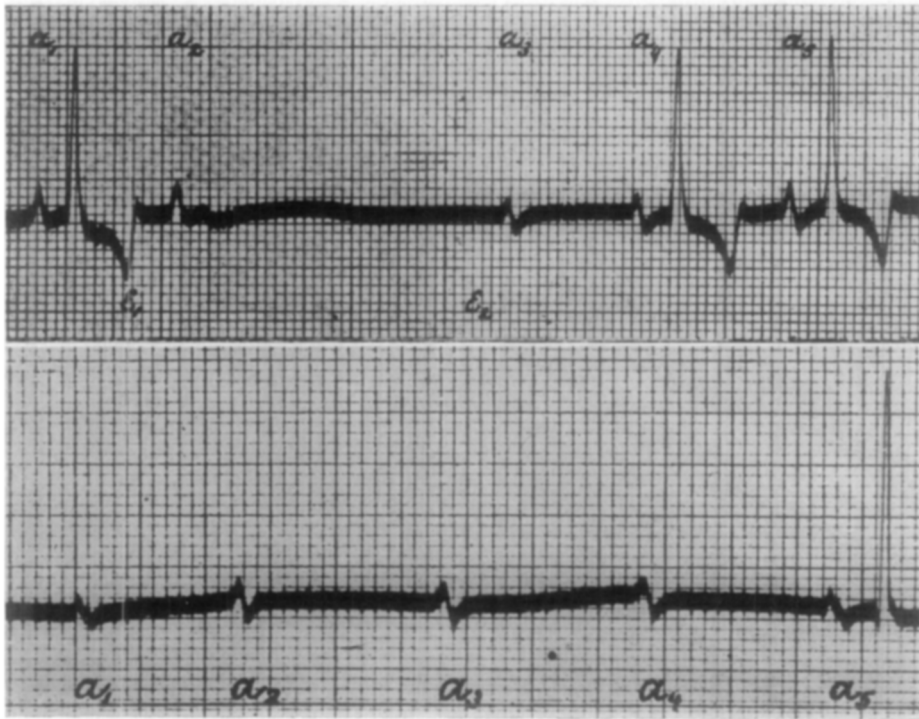


Fig. 34.

Fig. 33.—Dog. Heart block from vagal stimulation—right anterior to left posterior extremity.  
Fig. 34.—Dog. Following 3 second vagal arrest. Right anterior to left posterior extremity.

91. In rare cases one can find complete allorhythmia in human hearts. We have had the opportunity of recording the right hand-left foot telecardiogram in a woman presenting this finding, as shown in Figs. 2 and 3 on the large plate.

92. The patient's pulse was only 29. The auricular rhythm is entirely independent of the ventricular, and there are 10 or 11 auricular beats to every 4 ventricular. Since the latter is not an even fraction of the former, the P waves are unequally distributed among the ventricular complexes.

93. It is generally easy to recognize superposition of auricular and ventricular waves. Thus at  $a_5$  and  $a_{10}$  (Fig. 2, Plate I) we see a P wave between S and T, and at  $a_3$  and  $a_8$ , P waves along the descending limb of T.

94. In the first and last complexes of Fig. 3 (Plate I) the superpositions are noteworthy, the P exactly coincident with the peak of T, producing a higher and more acute T wave.

95. In the first ventricular complex of the illustration the auricular peak



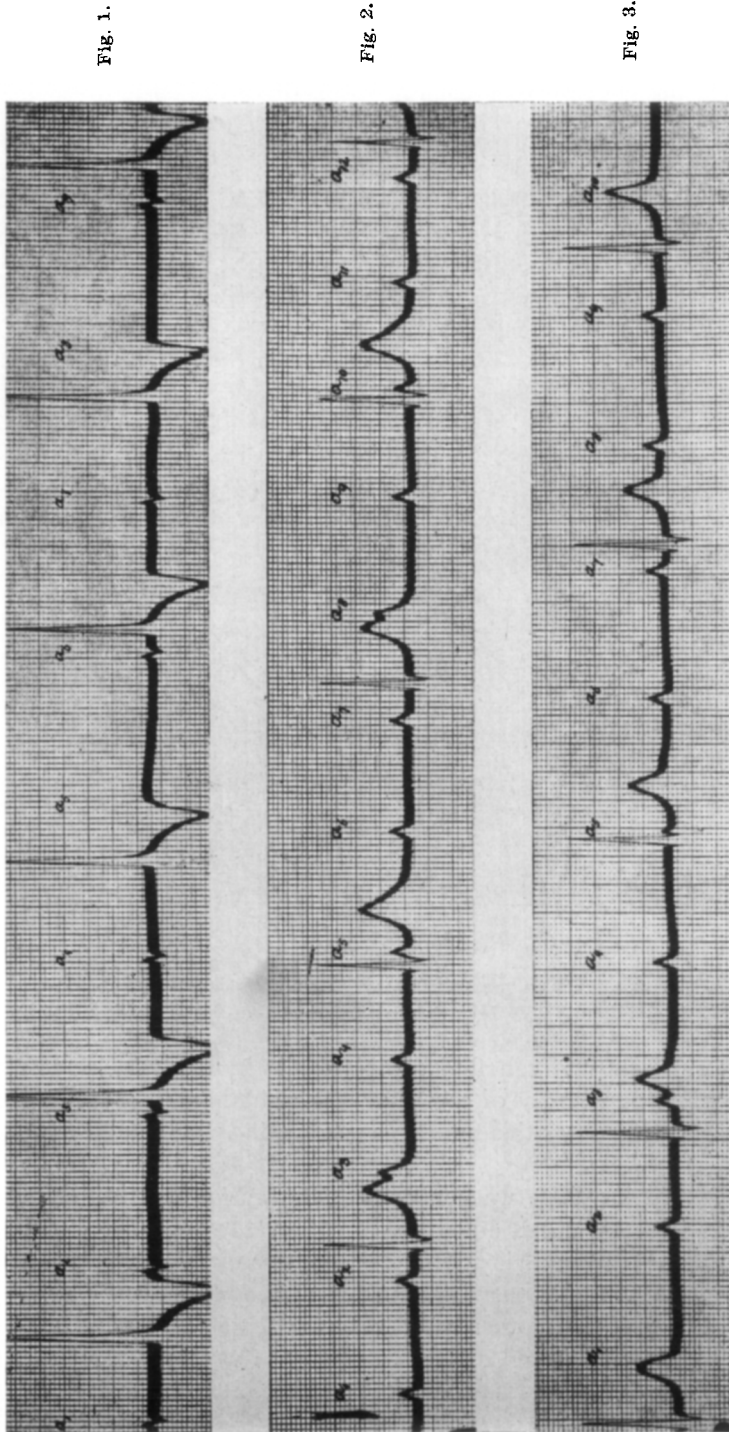


Fig. 1.

Fig. 2.

Fig. 3.

Plate I.—Ailorhythmia. Fig. 1, Dog. Fig. 2, S.V.G. Fig. 3, S.V.G.

occurs about 0.04 sec. after the peak of T with a resultant plateau formation rather than a point.

96. It is hardly necessary to say that the telecardiogram makes the certain diagnosis of these abnormalities very easy.

97. Though no atypical beats are seen in these records (Figs. 2, 3, Plate I) I have observed their occurrence in this patient. The abnormality of heart function in this case is thus more complicated than one might believe.

98. In an interesting clinical report published in the "Nederlandsch Tijdschrift voor Geneeskunde", Pel presents a similar case and emphasizes correctly the difficulty in mechanical recording of simultaneous heart motion and venous pulse. However, until now, this method of studying the relation between auricular and ventricular contraction had not been surpassed. Pel states it is ". . . an experiment which requires much time, is fine and delicate work, greatly taxes the patience of the demonstration audience, and gives most uncertain results."

99. In attempting to replace mechanical techniques with roentgen-ray studies, it seems to me that one would not get satisfactory results unless the transitory cardiac movements were recordable as graphic images.

100. Apropos mechanical records Pel says their measurement and analysis give false interpretations. He makes the somewhat imprudent prediction, ". . . that we will never be able to exclude the occurrence of excessively weak ventricular contractions in patients."

101. These problems, outlined vividly by Pel, do not present themselves in recording with telecardiograms. Almost all attempts are successful, quickly performed, and give an absolutely certain result. The method requires no particular skill on the part of the observer and combines precision with application of absolute measurements. While these are the arguments in favor of telecardiograms, we must not disregard the disadvantages.

102. The apparatus requires a special installation and takes up much space. Compared to ordinary cardiographs and sphygmographs it is expensive and complicated. It can only be handled by staff men trained to use it. It may be unreasonable to require of clinical assistants, whose studies are already so heavy, still more difficult technical study.

103. It is thus in the physiology laboratory that these apparati have their place and where this work should be carried out. Where there is this link, actual and figurative, between laboratory and hospital, and collaboration between physiologist and clinician, each remaining master in his territory, there one may fruitfully utilize these new electrical methods of research. I hope I have proved this to you.

104. In conclusion I would like to express my gratitude to Professor Bosscha and the Société Hollandaise des Sciences for their interest in my research and their support.

105. Others deserving of my appreciation are Professor Nolen and his assistants in the Academic Hospital. Not the least are my faithful aids in the Laboratory of Physiology: K. F. L. Van Der Woerd and H. J. W. Mens, and my ex-assistants H. J. Boeve, W. F. Theunissen, and L. C. de Jongh, whose graduate work has enabled me to present to you this communication on the telecardiogram.